



Case report and literature review of auto-brewery syndrome: probably an underdiagnosed medical condition

Fahad Malik,[©] Prasanna Wickremesinghe, Jessie Saverimuttu

To cite: Malik F, Wickremesinghe P, Saverimuttu J. Case report and literature review of auto-brewery syndrome: probably an underdiagnosed medical condition. *BMJ Open Gastro* 2019;6:e000325. doi:10.1136/bmjgast-2019-000325

Received 19 June 2019
Revised 21 July 2019
Accepted 23 July 2019

ABSTRACT

Auto-brewery syndrome (ABS), also known as gut fermentation syndrome, is a rarely diagnosed medical condition in which the ingestion of carbohydrates results in endogenous alcohol production. The patient in this case report had fungal yeast forms in the upper small bowel and cecum, which likely fermented carbohydrates to alcohol. Treatment with antifungal agents allowed subsequent ingestion of carbohydrates without symptoms. He had been exposed to a prolonged course of antibiotics before this occurred. We postulate that the antibiotic altered his gut microbiome, allowing fungal growth. This diagnosis should be considered in any patient with positive manifestations of alcohol toxicity who denies alcohol ingestion. The aim of this case report was confirmation and treatment of ABS using a standardised carbohydrate challenge test followed by upper and lower endoscopy to obtain intestinal secretions to detect fungal growth. These fungi were speciated and antifungal sensitivity performed. This allowed the use of appropriate therapy. The patient was kept on a carbohydrate-free diet during the initial 6-week period of therapy. A single-strain probiotic for competitive inhibition of fungal growth was given to the patient. This probiotic was later replaced by a multistrain bacterial probiotic hoping that the multiple bacteria would inhibit fungi better than a single-strain. The beneficial role of probiotics in this condition has not been studied. The patient was rechallenged for endogenous alcohol production prior to reintroducing carbohydrates in his diet.

INTRODUCTION

Auto-brewery syndrome (ABS), also known as gut fermentation syndrome, is a rarely diagnosed medical condition where ingested carbohydrates are converted to alcohol by fungi in the gastrointestinal tract. Patients with this condition become inebriated and suffer all the medical and social implications of alcoholism, including arrest for drunken driving. This report details the case of a patient who manifested many of the alcohol-related symptoms yet claimed repeatedly that he had not ingested any alcohol. Fungi are not commonly known to be present in the stomach and upper small intestine of healthy

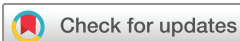subjects.¹ The colon, however, can harbour some fungi which live commensally.

CASE HISTORY

A previously active, healthy, 46-year-old man (height, 6 feet 2 inches; weight, 230 lbs; body mass index, 30 kg/m²) with no significant medical or psychiatric history sought our help for the confirmation and treatment of ABS. He was not taking any medications, including herbal or over-the-counter drugs. He complained of having had memory loss, mental changes, and episodes of depression for over 6 years starting in January of 2011. These changes started to occur after he received antibiotic therapy (cephalexin 250 mg orally three times a day for 3 weeks) for a complicated traumatic thumb injury. One week after the completion of his antibiotic therapy, personality changes with episodes of depression, 'brain fog', and aggressive behaviour became apparent, which was very uncharacteristic for him. He was initially evaluated by his primary care physician (PCP) for the first time in January of 2014 before being referred to a psychiatrist who treated him with lorazepam and fluoxetine.

One morning, he was arrested for presumed driving while intoxicated (DWI). He refused a breathalyser analysis and was hospitalised. His initial blood alcohol level was 200 mg/dL. The hospital personnel and police refused to believe him when he repeatedly denied alcohol ingestion. He recovered fully and was discharged.

After hearing about a similar successfully treated case by a physician in Ohio, his aunt purchased a breathalyser to record his breath alcohol levels and persuaded him to visit Ohio for the treatment, where basic laboratory testing (complete blood count, comprehensive metabolic panel, immunology panel, and urinalysis) were all normal. A comprehensive stool analysis was negative for *Giardia* and *Cryptosporidium*. The patient's lactoferrin,



© Author(s) (or their employer(s)) 2019. Re-use permitted under CC BY-NC. No commercial re-use. See rights and permissions. Published by BMJ.

Internal Medicine, Richmond University Medical Center, Staten Island, New York, USA

Correspondence to

Fahad Malik;
fahadimalik@live.com



calprotectin, and lysozyme levels and stool malabsorption studies were also normal. *Saccharomyces cerevisiae* (brewer's yeast) and *S. boulardii* were detected in his stool addition to his normal stool bacterial flora. On antifungal sensitivity testing, these *Saccharomyces* strains were found to be sensitive to azoles and nystatin.

To confirm the diagnosis of ABS, the patient was given a carbohydrate meal, and his blood alcohol levels were monitored under observation. After 8 hours, his blood alcohol level was elevated to 57 mg/dL. He was then treated for the *Saccharomyces* fungi found in his stool with oral fluconazole 150 mg per day for 14 days. In the absence of improvement, on day 10, this was changed to nystatin 500 000 IU three times a day for another 10 days. His symptoms improved, and he was discharged on a strict carbohydrate-free diet along with special supplements given by his Ohio physician, but no further antifungal therapy was prescribed.

After a few weeks of being asymptomatic, intermittent 'flares' returned. He was seen by many internists, psychiatrists, neurologists, and gastroenterologists who were unable to help him to return to his previous state of health. The most significant event caused by one of his inebriations was a fall that caused intracranial bleeding and necessitated a transfer to a regional neurosurgical centre, where he had a complete spontaneous recovery in 10 days. In this institution, his blood alcohol levels ranged from 50 to 400 mg/dL. Here too, the medical staff refused to believe that he did not drink alcohol despite his persistent denials.

Due to worsening symptoms, he searched for help from an online support group and contacted us. This patient physical examination was entirely normal. Prior to his thumb injury, he had been a light social drinker but completely abstained from alcohol thereafter. His construction company was involved in restoring hurricane-damaged houses, many of which had mould contamination. To investigate this patient's condition further, we collected gastrointestinal secretions using upper and lower endoscopy to detect fungi. The patient's upper and lower endoscopic procedures were normal. Fungal cultures obtained from the upper small gut and cecal secretions grew *Candida albicans* and *C. parapsilosis*. Antifungal sensitivity testing was done for these fungi, and both were sensitive to azoles. His secretory immunoglobulin A was elevated to 607 mg/dL. *Helicobacter pylori* infection was not detected in his gastric antral biopsy. The patient agreed to be treated in collaboration with his local PCP because he lived far away from our hospital.

Given his prior exposure to fluconazole, we decided to use oral itraconazole 150 mg per day as an initial antifungal therapy for *S. cerevisiae* and *Candida* species. After 10 days, as his symptoms did not improve, so this dose was increased to 200 mg per day, and the patient became completely asymptomatic. Unbeknownst to us, he ate pizza and drank soda while on this treatment, resulting in a severe ABS relapse. We then decided to treat him with intravenous micafungin 150 mg per day for 6 weeks.

After completing this therapy, his gastrointestinal secretions were again studied and cultured by repeat upper and lower endoscopy. At this time, no fungal growth was present. The patient monitored his breath alcohol levels two times a day throughout the treatment process with instructions to inform us immediately if positive. He was started on a probiotic (single-strain *Lactobacillus acidophilus* with 3 billion colony-forming units per capsule) to competitively inhibit fungi and help to normalise his gut flora.² Carbohydrates were then gradually introduced in his diet, and a repeat carbohydrate challenge test was negative. After 6 weeks, this probiotic was changed to a multi-strain probiotic, which contains 12 different bacterial organisms without any fungi.³⁴ He has since continued this treatment. Approximately 1.5 years later, he remains asymptomatic and has resumed his previous lifestyle, including eating a normal diet while still checking his breath alcohol levels sporadically. A summarise format of the time course of events and interventions is presented in table 1.

DISCUSSION

ABS is probably an underdiagnosed condition. We believe that our patient's symptoms were triggered by exposure to antibiotics, which resulted in a change in his gastrointestinal microbiome allowing fungal overgrowth. *Candida* and *S. cerevisiae*, which can convert carbohydrates to endogenous alcohol, were detected in his intestinal secretions and stool. *S. cerevisiae* is known to use acetate for anaerobic alcohol fermentation.²⁵ A large Middle Eastern study involving 1400 subjects who were teetotalers detected very small endogenously produced alcohol levels using gas chromatography and mass spectrometry. This study was done to establish gastrointestinal alcohol levels to advise on legal limits.⁶

The first large case series of ABS was reported in the Japanese literature in the 1970s which exhibited *Candida* species.⁷ Ten years later, the first US cases were published.⁸⁻¹⁰ Previous case reports had described patients who were immunocompromised or had strictures in Crohn's disease with bacterial overgrowth or short gut syndrome after surgery.^{2 3 7 11-14} To the best of our knowledge, antibiotic exposure initiating ABS has not been previously reported.

To confirm an ABS diagnosis, we suggest a standardised carbohydrate challenge test rather than a non-specific carbohydrate meal, as this patient received in Ohio. There are currently no established diagnostic criteria to confirm an ABS diagnosis or treat this condition. We, therefore, propose the following protocol for this. It is important to make certain that patients with suspected ABS who have elevated blood or breath alcohol levels are not surreptitiously drinking. In our provocative carbohydrate challenge test, we gave the patient 200 g of glucose by mouth after an overnight fast with blood drawn at timed intervals of 0, ½, 1, 2, 4, 8, 16, and 24 hours for glucose and blood alcohol levels. This test can be aborted

Table 1 Summary of events

Approximated time	Event	Result/response
January 2011	A 46-year-old man from North Carolina with traumatic thumb injury treated with cephalexin 250 mg for 3 weeks.	Mental status changes, brain fog, and depression (commonly after meals)
January 2014	Seen a psychiatrist for the first time and began treatment with lorazepam and fluoxetine.	Partial improvement
March 2014	Hospitalised after DWI*, patient denied any alcohol ingestion. Began self-monitoring his BAL using a breathalyser.	BAC elevated (200 mg/dL) Intermittently positive without any alcohol intake.
March 2015	Travelled to Ohio seeking treatment.	
May 2015	Stool testing performed.	<i>Saccharomyces cerevisiae</i> (brewer's yeast)
September 2015	A carbohydrate challenge meal (50 g) was given and alcohol levels were measured while under complete observation.	Blood alcohol level was increased to 57 mg/dL in 8 hours.
September 2015	Started on a carbohydrate-free diet with fluconazole 150 mg per day. It was later changed to nystatin 50 000 IU due to lack of effect. Continued to seek further treatment and he consulted multiple physicians over 2 years.	Mental status slightly improved but brain fog returned in a few weeks. No significant clinical improvement.
February 2017	Patient hospitalised again for intracranial bleeding after a fall while inebriated.	Inpatient BAC fluctuated 50–400 mg/dL during this entire time.
September 2017	He travelled to New York seeking further management due to recurrent symptomatic flares.	
September 2017	Upper and lower endoscopy were performed and gastrointestinal secretions were collected.	<i>C. albicans</i> and <i>C. parapsilosis</i> were detected.
September 2017	Started on daily itraconazole 150 mg (later increased to 200 mg) while continuing a carbohydrate-free diet.	Became completely asymptomatic.
October 2017	While on treatment, he consumed pizza and soda.	Severe relapse of ABS requiring hospitalisation once again.
January 2018	A peripherally inserted central catheter was inserted and started on micafungin 150 mg per day for 6 weeks.	Complete resolution of symptoms.
February 2018	After completion of antifungal therapy, a repeat study of gastrointestinal secretions via endoscopy was done.	No fungal growth detected.
February 2018	Provocative carbohydrate challenge test performed.	Breathalysers and blood alcohol levels both became negative.
May 2019	Patient was being followed by his primary care physician while gradually reintroducing carbohydrates to his diet.	He remains asymptomatic on a normal diet for about 1.5 years.

*Legal DWI concentration limit=0.08% or 8 mg/dL.

ABS, auto-brewery syndrome; BAC, blood alcohol concentration; BAL, breath alcohol level; *C. albicans*, *Candida albicans*; *C. parapsilosis*, *Candida parapsilosis*; DWI, driving while intoxicated.

early if alcohol levels become elevated in the first few hours. The delayed sample testing at 16 and 24 hours becomes important if the initial samples are negative as some fungi can take 24 hours or longer to convert carbohydrate substrates to alcohol (figure 1). Non-standardised carbohydrate challenge testing has previously been used to diagnose ABS.^{2 3 12–14} The patient was under observation for the duration of the test.

Concomitant breath analysis testing was done to validate the accuracy of the patient's breathalyser values. The accuracy of the breathalyser is of paramount importance when a patient uses this device to self-monitor their breath alcohol levels during and after treatment. The widespread availability of breathalysers has facilitated the

diagnosis and monitoring of these patients. Breathalysers can be obtained without difficulty on the Internet or via appropriate sales outlets. It is also important to note that the breathalyser should be calibrated or replaced every 30 days to remain accurate.

Our patient had an elevated blood alcohol level of 57 mg/dL 8 hours after the carbohydrate meal in Ohio, but a concomitant breathalyser was not done. We propose that gastrointestinal secretions should be obtained by upper and lower endoscopy, at which time the macroscopic gut morphology and any coexisting pathologies can be documented. Secretions collected from the stomach, upper small bowel, colon, and terminal ileum for pH, Gram stain, and bacterial and fungal cultures

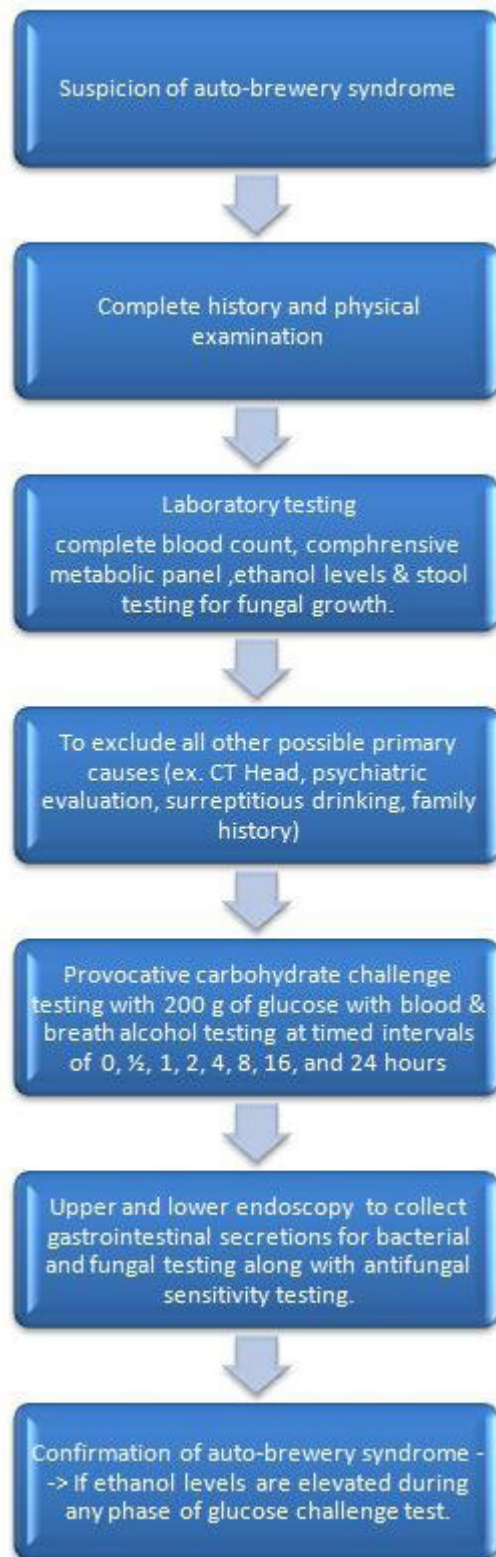


Figure 1 Protocol for the detection of auto-brewery syndrome.

should be performed. These samples should also be sent to a special laboratory for fungal speciation and antifungal sensitivity testing. To the best of our knowledge, endoscopy has not been used previously to acquire

gastrointestinal secretions for this purpose. We believe that endoscopy is an important intervention because it allows us to obtain upper and lower gastrointestinal secretions, while some fungi could be present in the colon, presence of fungi in the stomach and upper intestinal tract is likely pathological.¹

After completing 6 weeks of antifungal treatment, the subject was instructed to continue to monitor his breath alcohol levels two times a day and to inform the physicians of any positive results. It would be ideal for patients with ABS to be re-evaluated using another carbohydrate challenge test prior to increasing their oral carbohydrate intake. Our patient no longer has elevated blood alcohol levels nor did he note any increase in breathalyser values when challenged again with 200 g of carbohydrates. His repeat gastrointestinal secretions showed no fungi.

The role of probiotic use in ABS is unstudied. A previous case report showed beneficial use of probiotic for re-colonisation of digestive tract.² We are also aware of a recent publication showing that probiotics administered after *Clostridium difficile colitis* following antibiotic use may delay recovery of the intestinal microbiome.¹⁵ We thought it was reasonable to begin our patient's treatment with a carbohydrate-free diet and antifungal therapy, as well as a probiotic, to competitively inhibit fungal growth in his gut.^{3 4} We chose a single-strain *L. acidophilus* with 3 billion colony-forming units per capsule for this purpose. Approximately 6 weeks later, this single-strain *L. acidophilus* probiotic was discontinued. A multistrain purely bacterial probiotic was substituted as we thought that this would be more beneficial in maintaining a healthy and diverse microbiome.

In conclusion, it should be noted that the earliest symptoms of ABS may be mood changes, delirium, and brain fog rather than the medical manifestation of alcohol inebriation. A multidisciplinary approach with early psychiatrist involvement is suggested. Any patient denying alcohol ingestion but who have elevated blood alcohol levels or positive breathalyser results should be investigated for ABS. This should involve all patients arrested for DWI who deny alcohol ingestion. We believe that alcohol, whether exogenous or endogenously produced, could have the same toxic manifestations. This is a condition that is treatable with dietary modifications, appropriate antifungal therapy, and possibly probiotics. The use of probiotics and faecal microbiota transplantation could be considered for future studies. We are only starting to recognise the complexity of ABS and are currently studying more patients with possible ABS using the proposed protocol for diagnosis and treatment.

Acknowledgements Thanks to Dr Himanga Kalina, Department of Research of our institute, for assisting us with the study.

Contribution FM and PW planned, conducted, and wrote the manuscript. JS and PW edited and supervised the manuscript.

Funding The authors have not declared a specific grant for this research from any funding agency in the public, commercial, or not-for-profit sectors.

Competing interests None declared.

Patient consent for publication Obtained.

Provenance and peer review Not commissioned; externally peer reviewed.

Open access This is an open access article distributed in accordance with the Creative Commons Attribution Non Commercial (CC BY-NC 4.0) license, which permits others to distribute, remix, adapt, build upon this work non-commercially, and license their derivative works on different terms, provided the original work is properly cited, appropriate credit is given, any changes made indicated, and the use is non-commercial. See: <http://creativecommons.org/licenses/by-nc/4.0/>.

REFERENCES

1. Lauwers G, Mino-Kenudson M, Kradin RL. Infections of the gastrointestinal tract. In: Kradin Richard L, ed. *Diagnostic pathology of infectious disease*. Philadelphia: Elsevier, 2010: 232–70.
2. Cordell B, McCarthy J. A Case Study of Gut Fermentation Syndrome (Auto-Brewery) with *Saccharomyces cerevisiae* as the Causative Organism. *Int J Clin Med* 2013;04:309–12.
3. Painter K, Sticco KL. *Auto-brewery syndrome (gut fermentation)*. Treasure Island, FL: StatPearls Publishing, 2019.
4. Sam Q, Chang M, Chai L. The fungal Mycobiome and its interaction with gut bacteria in the host. *Int J Mol Sci* 2017;18:330.
5. Henningsen BM, Hon S, Covalla SF, et al. Increasing anaerobic acetate consumption and ethanol yields in *Saccharomyces cerevisiae* with NADPH-specific alcohol dehydrogenase. *Appl Environ Microbiol* 2015;81:8108–17.
6. Mostafa A, Ragab Ahmed R, Al-Mazroua Maha K, et al. Endogenous ethanol production levels in Saudi Arabia residents. *J Alcohol Drug Depend* 2015;3.
7. Iwata K. *A review of the literature on drunken syndromes due to yeasts in the gastrointestinal tract*. Tokyo, Japan: University of Tokyo Press, 1972: 260–8.
8. Geertinger P, Bodenhoff J, Helweg-Larsen K, et al. Endogenous alcohol production by intestinal fermentation in sudden infant death. *Z Rechtsmed* 1982;89:167–72.
9. Kaji H, Asanuma Y, Yahara O, et al. Intragastrointestinal alcohol fermentation syndrome: report of two cases and review of the literature. *J Forensic Sci Soc* 1984;24:461–71.
10. Bivin WS, Heinen BN. Production of ethanol from infant food formulas by common yeasts. *J Appl Bacteriol* 1985;58:355–7.
11. Ladkin RG, Davies JNP. Rupture of the stomach in an African child. *Br Med J* 1948;1:644.
12. Fayemiwo SA, Adegboro B. Gut fermentation syndrome. *African J Clin Exp Microbiol* 2014;15.
13. Hunnisett A, Howard J, Davies S. Gut Fermentation (or the 'Auto-brewery') Syndrome: A New Clinical Test with Initial Observations and Discussion of Clinical and Biochemical Implications. *J Nutri Med* 1990;1:33–8.
14. Dahshan A, Donovan K. Auto-brewery syndrome in a child with short gut syndrome: case report and review of the literature. *J Pediatr Gastroenterol Nutr* 2001;33:214–5.
15. Suez J, Zmora N, Zilberman-Schapira G, et al. Post-Antibiotic gut mucosal microbiome reconstitution is impaired by probiotics and improved by autologous FMT. *Cell* 2018;174:1406–23.